

CONFIDENCE® NATURAL					
LARGE POUCH					
SIZE	STARTER HOLE	PRE-CUT	ORDER CODES		PACK SIZE
			Transparent	Trans/Overlap	
13mm	•	–	NLT13*	NL13*	30
STANDARD POUCHES					
SIZE	STARTER HOLE	PRE-CUT	ORDER CODES		PACK SIZE
			Transparent	Trans/Overlap	
13mm	•	–	NT13*	N13*	30
25mm	–	•	–	N25	30
28mm	–	•	–	N28	30
32mm	–	•	–	N32	30
35mm	–	•	–	N35	30
38mm	–	•	–	N38	30
41mm	–	•	–	N41	30
MINI POUCH					
SIZE	STARTER HOLE	PRE-CUT	ORDER CODE		PACK SIZE
			Transparent	Trans/Overlap	
13mm	•	–	–	NM13*	30
LARGE DRAINABLE POUCH					
SIZE	STARTER HOLE	PRE-CUT	ORDER CODES		PACK SIZE
			Transparent	Trans/Overlap	
13mm	•	–	NDLT13*	NDL13*	30
STANDARD POUCHES					
SIZE	STARTER HOLE	PRE-CUT	ORDER CODES		PACK SIZE
			Transparent	Trans/Overlap	
13mm	•	–	NDT13*	ND13*	30
25mm	–	•	–	ND25	30
28mm	–	•	–	ND28	30
32mm	–	•	–	ND32	30
35mm	–	•	–	ND35	30
SMALL DRAINABLE POUCH					
SIZE	STARTER HOLE	PRE-CUT	ORDER CODE		PACK SIZE
			Transparent	Trans/Overlap	
13mm	•	–	–	NDS13*	30
STANDARD POUCHES			SMALL POUCH		
SIZE	ORDER CODES	PACK SIZE	SIZE	ORDER CODE	PACK SIZE
	Trans/Overlap			Trans/Overlap	
13mm	NU13*	10	13mm	NUS13*	10
25mm	NU25	10			
28mm	NU28	10			
32mm	NU32	10			
35mm	NU35	10			

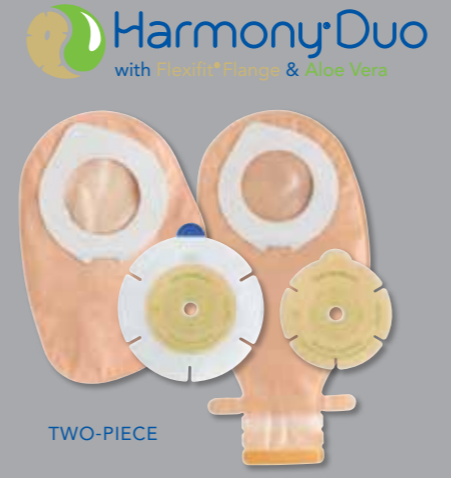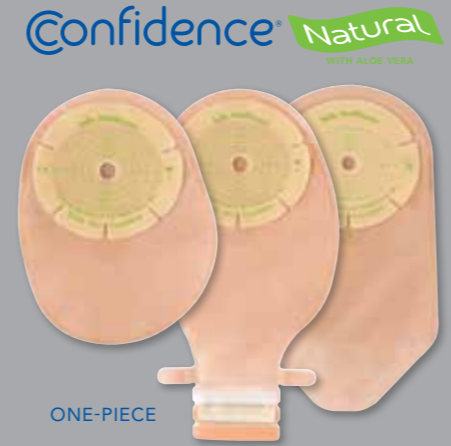HARMONY® DUO					
STANDARD FLANGES – with Flexifit® and Aloe Vera			FLEXIBLE FLANGES – with hydrocolloid surround, Flexifit® and Aloe Vera		
SIZE	ORDER CODES	PACK SIZE	SIZE	ORDER CODES	PACK SIZE
13–32mm	FHD1332	10	13–32mm	FHDF1332	10
13–50mm	FHD1350	10	13–50mm	FHDF1350	10
13–70mm	FHD1370	10	13–70mm	FHDF1370	10
LARGE CLOSED POUCHES			STANDARD CLOSED POUCHES		
SIZE	ORDER CODES	PACK SIZE	SIZE	ORDER CODES	PACK SIZE
	Opaque			Opaque	
13–32mm	HDCL1332	30	13–32mm	HDC1332	30
13–50mm	HDCL1350	30	13–50mm	HDC1350	30
13–70mm	HDCL1370	30	13–70mm	HDC1370	30
MINI CLOSED POUCHES					
SIZE	ORDER CODES Opaque		PACK SIZE		
13–32mm	HDCM1332		30		
13–50mm	HDCM1350		30		
13–70mm	HDCM1370		30		
LARGE DRAINABLE POUCHES					
SIZE	ORDER CODES		PACK SIZE		
	Transparent	Trans/Overlap			
13–32mm	–		HDDL1332 30		
13–50mm	HDDL1350		HDDL1350 30		
13–70mm	HDDL1370		HDDL1370 30		
STANDARD DRAINABLE POUCHES			SMALL DRAINABLE POUCHES		
SIZE	ORDER CODES	PACK SIZE	SIZE	ORDER CODES	PACK SIZE
	Trans/Overlap			Trans/Overlap	
13–32mm	HDD1332	30	13–32mm	HDDS1332	30
13–50mm	HDD1350	30	13–50mm	HDDS1350	30
13–70mm	HDD1370	30	13–70mm	HDDS1370	30

* Starter hole wafers can be cut up to 70mm wide and 55mm deep.

For more information and free samples please call
FREEPHONE 0800 626388 (UK),
FREEPHONE 1-800 408508 (Ireland)
 or visit www.saltsstomacare.co.uk
Overseas customers can contact our International
Customer Services Team: Telephone: +44 (0) 121 333 2000
 or email: international@salts.co.uk



©Registered trade marks of Salts Healthcare Ltd. ©Salts Healthcare Ltd 2011. Products and trade marks of Salts Healthcare Ltd are protected by UK and foreign patents, registered designs and trade marks. For further details, please visit www.salts.co.uk



PATIENT CASE STUDIES

featuring Flexifit® technology



Validating Salts research into healthy stoma skin

SALTS
HEALTHCARE
Excellence in stoma care

PATIENT HISTORY

- 74 year old male
- Underwent a cystoprostatectomy and formation of ileal conduit for transitional cell carcinoma of the bladder in October 2009
- Lifelong smoker who suffers with angina, hypertension and mild chronic obstructive pulmonary disease (COPD). He required thorough anaesthetic assessment and medical optimisation prior to his surgery
- Patient is married and, despite his medical problems, he still leads a full life, enjoys looking after his grandchildren, has a wide circle of friends and still drives, walks his dog and plays bowls

OBSERVATIONS ON REFERRAL

- When the stents were removed and the patient was encouraged to mobilise, he was disconnected from the night drainage bag and became independent with the management of his stoma. However, he began to have problems with the pouch leaking
- He was provided with a soft convex pouch and a belt. Initially, he was reluctant to wear the belt. But when he discovered that the pouching system lasted 3 days and could be relied upon, he was happy to continue using it
- Patient was embarrassed about the leaks and was becoming increasingly anxious about how he would manage this at home. He felt that he would never be able to resume his usual activities and would become housebound and a burden to his wife because of the additional laundry

COMMUNITY FOLLOW-UP

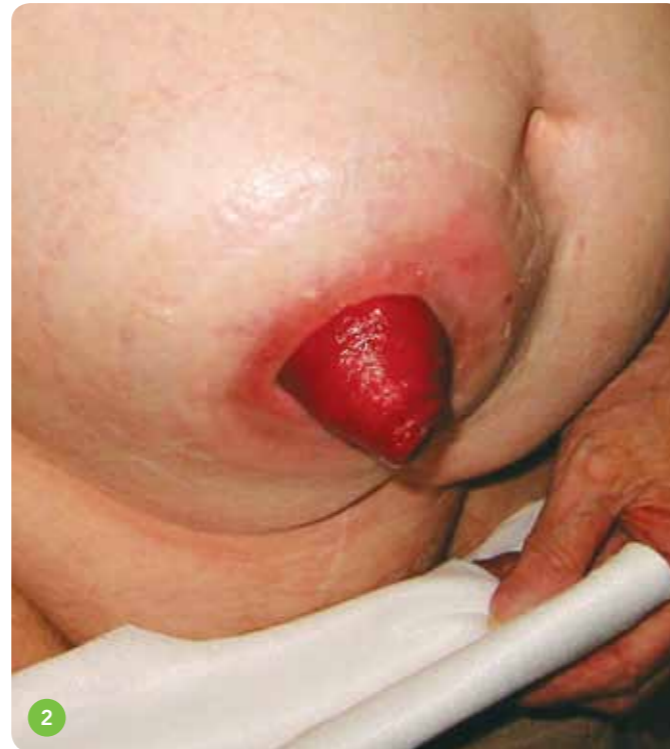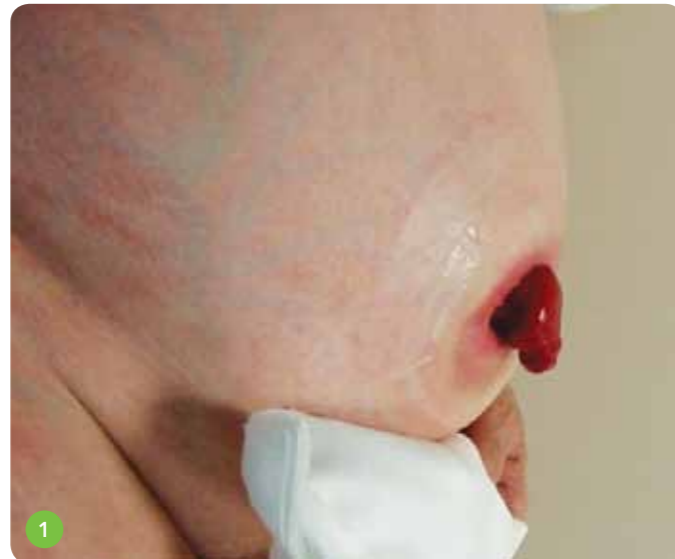- Following discharge, the patient made good progress, both physically and psychologically and during his

6-monthly follow-up appointment he discussed the possibility of playing bowls. He was also measured for a hernia support garment as a prophylactic measure and advised about its use

- At his next 6-month review, all was going well and the patient was very positive, even agreeing to become a patient advocate and discuss the impact of stoma surgery with other potential patients

COMPLICATIONS

- A few weeks prior to his scheduled annual follow-up appointment, the patient contacted the department as he was concerned that he had developed a lump behind his stoma. The pouches were no longer adhering well to his skin despite the use of wafer extensions which had been recommended by a company representative while the patient was attending a support group meeting



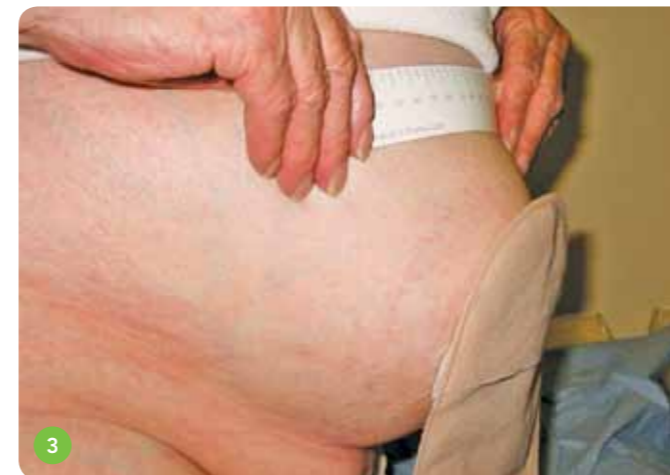- He had experienced several episodes of leakages, once while he was in a supermarket. He was so embarrassed, he'd abandoned his shopping and driven straight home
- The patient began to curtail his social activities as he was worried that he would have a leak. All of the anxieties that had been present in his early post-operative days were being realised and he found it more distressing now, since he had been coping well previously
- He had delayed asking for help as he believed that he has been supplied with faulty stoma bags and thought that nothing could be done. He had also started changing the pouches daily, thinking that the adhesive

was weak and not lasting for the 3 days that he had become accustomed to

- On examination, it was clear that he had developed a parastomal hernia and the relative rigidity of the soft convex wafer would not mould around the bulge on his abdomen

TREATMENT

- Confidence® Natural urostomy pouch was the first option I decided to try because of the Flexifit® wafer and the specially developed urostomy adhesive. Despite recommending the product, there was some anxiety on my part that there was no convexity and no integral belt loops for wearing a belt
- The pouch immediately moulded itself around the patient's hernia and he commented on how comfortable it felt. He was also pleased not to have to wear the belt, which he had accepted but had never really liked. He was supplied with enough pouches to last a month, based on changing them on alternate days, and



booked in for a follow-up appointment in 2 weeks to assess effectiveness

- At the 2-week follow-up appointment, the patient was very happy with the results. He had been changing the pouch on alternate days as instructed but when he examined the wafer during pouch changes, he noticed very little erosion and felt they would last longer
- Furthermore, he had experienced no leaks during this period. He was particularly pleased not to have to wear a belt and felt that his confidence was returning

OUTCOME

- On attending clinic, the patient was feeling very pleased with the results: he was changing the pouch every 3 days, had experienced no episodes of leakages, and was planning to go away for the Christmas holidays to stay with family – something he would never have contemplated prior to the product change due to the fear of soiling in someone else's house
- The cost implication for the NHS was also considerable

COSTS – PREVIOUSLY:

Convex pouches per month (x30)	£165.00
Wafer extensions per month (x60)	£27.75
Belts (2 per month)	£6.00
Total per month	£198.75

COSTS – CURRENT:

10 Confidence® Natural pouches per month	£47.00
Total saving per month	£151.75
Annual saving	£1,821.00

Hugely beneficial psychological impact – increasing self-esteem

Regained the confidence to undertake social engagements

The cost implications of this appliance change were considerable

CONCLUSION

- The use of Salts Confidence® Natural with this patient had a hugely beneficial psychological impact – increasing self-esteem which had gradually been eroded by persistent leaks
- He regained the confidence to undertake a number of social engagements which most of us would take for granted
- He also found the pouches were comfortable to wear, stating that, at times, he 'forgot it was there'
- The cost savings of this appliance change were considerable

PATIENT HISTORY

- 82 year old male
- Lives alone
- His wife died 10 years previous of rectal cancer
- Very active and is the captain of the local bowls team
- Member and organiser of a walking group
- He has a lady friend and goes on holidays with her – their social life is very full
- 2008: diagnosed with a rectal cancer, but he was very positive
- Anterior Resection with loop Ileostomy in July 2008
- He coped well with the stoma and continued with his active life
- The cancer histology was a Dukes B and he was a surgical follow-up, needing no further treatment

OBSERVATION ON REFERRAL

- The stoma was reversed in December 2008. Patient was incontinent, with very little sphincter control
- He took loperimide and had a little more control
- In May 2009, the patient became breathless and had chest pain
- He was diagnosed with a primary lung cancer
- Referred to Hull for surgery and had a lung resection. He was told he would suffer from lots of gas
- He recovered well from the surgery but was miserable with the incontinence
- He stopped going out, gave up bowling and walking
- He tried to socialise with his lady friend but found it embarrassing
- I visited this patient on 3 occasions and counselled him regarding another stoma to aid the problem
- The surgery was booked twice but patient changed his mind each time because he'd had 3 or 4 'good days'

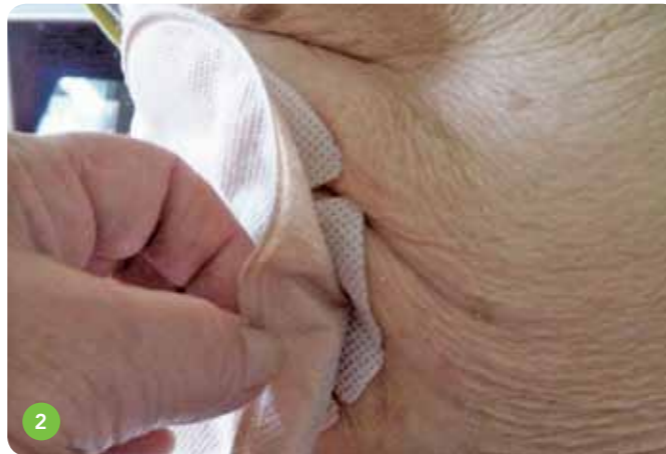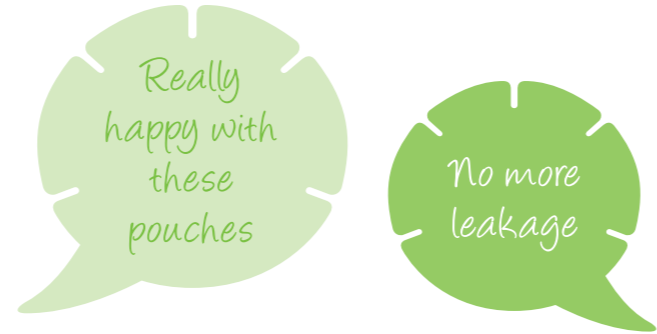
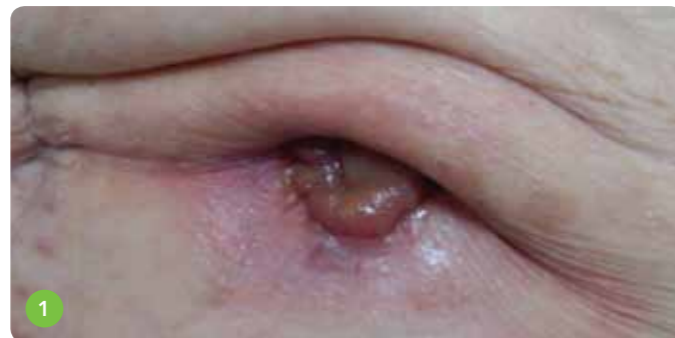- Eventually, he rang to say he couldn't cope any more so wanted the surgery as soon as possible
- He felt his life was over
- March 2011: Hartmann's procedure. Patient had a stormy recovery but was eventually discharged home with a supply of soft convex pouches
- I visited 2 days post-discharge to find a very miserable man who had changed his bedding twice and thrown away his bedside rugs

1st VISIT

- Abdomen very wrinkled
- Hooded stoma which had been difficult to site (Ref 1)
- We tried to put on the convex bag, lifting the abdomen flat
- I put SecuPlast® Hydro extension strips on and a belt to secure and the district nurse visited each day over the weekend

2nd VISIT

- Patient was miserable and wished he hadn't had the procedure done
- I fitted Confidence® Natural and it moulded snugly around the hood and creases (Ref 2)



CONCLUSION

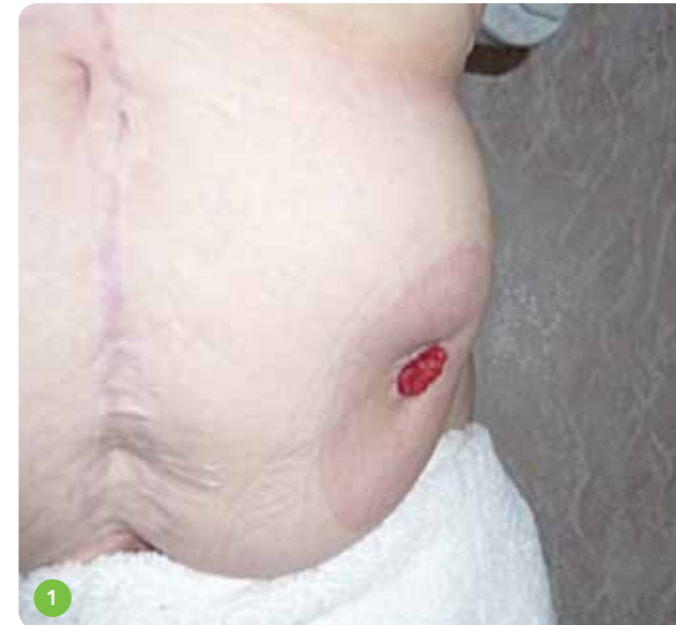- Patient has had no further leakage and is really happy with the pouch
- However, he suffers from excessive, noisy wind which is stopping him from getting back to normality
- He is very negative and can't see a way around this situation. We have discussed diet etc
- The colorectal CNS, the psychologist and myself are meeting up with the patient to try and resolve these additional issues

PATIENT HISTORY

- 58 year old female
- 2000 – Hartmann's colostomy
- 2003 – Excision of rectum
- 2005 – Laparoscopic parastomal hernia repair, using a polypropylene mesh
- 2009 – Laparotomy and surgical repair of irreducible parastomal hernia (second complicated hernia repair)

OBSERVATION ON REFERRAL

- Recurrent bulge (Ref 1)
- Discomfort
- Dragging sensation
- Irregular bowel pattern, causing frequent pouch changes, thus causing occasional sore skin
- A poor body image

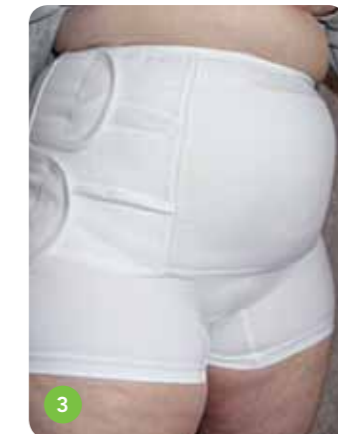
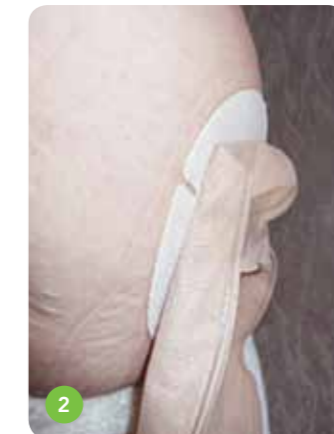
TREATMENT

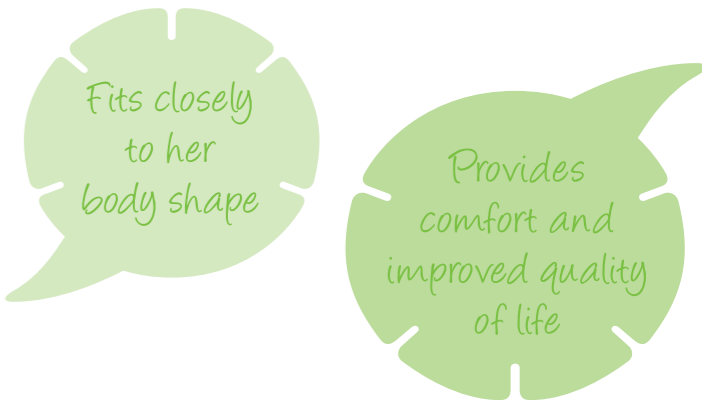
- The previous appliance was not satisfactory for the patient as it caused wrinkling, and leakages occurred due to poor adhesion from the bulkiness around the hernia
- This lady now chose to wear a drainable pouch due to her erratic bowel function, often requiring 3 or 4 pouch changes a day. This sometimes resulted in sore skin under the wafer

OUTCOME

- Since using the new Salts Confidence® Natural with Aloe Vera, the skin is no longer sore and she chooses to change her pouch daily
- Wearing Confidence® Natural with its unique five-sided Flexifit® wafer and soothing Aloe Vera (Ref 2)
- Fits closely to her body shape, offering her a perfect fit
- Following her first stomal hernia repair, support pants were used to help support the abdomen. She found these comfortable to wear
- After the second hernia repair, an abdominal support



- was recommended and she tried several commercial company corsets, but found them quite uncomfortable. None helped with relieving her discomfort from the hernia
- After attending an exhibition, she found a new support belt, and since then wears it most of the time over Salts Simplicity pants (Ref 3)
- She feels the corset stops the dragging, and supports and flattens the abdomen. This, hopefully, will prevent the hernia getting worse, as well as giving her a better body image



CONCLUSION

- Parastomal hernia repair is associated with high rates of morbidity, mortality and recurrence. The management of a parastomal hernia is a common clinical dilemma
- Comfort and security from leaks is paramount to the patient
- Using a stoma pouch that can provide this will enhance and improve quality of life
- Salts Confidence® Natural worked for this lady

PATIENT CASE STUDY No.4 (UK) Confidence® Natural Drainable

SHAPE

PATIENT HISTORY

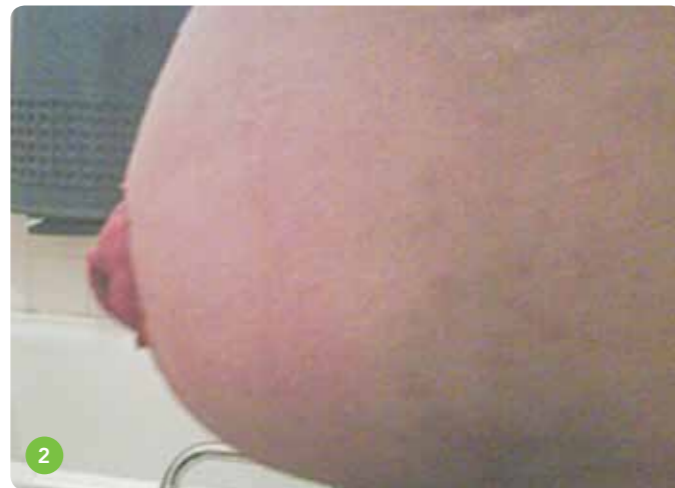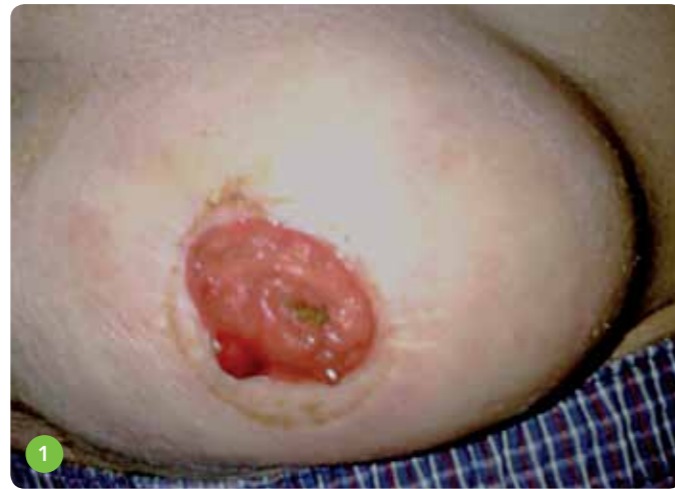- 68 year old male
- Abdoperineal resection of rectum, 2007
- Rectal Adenocarcinoma
- Parastomal hernia, 2009 – no surgery
- Hypertension
- Type 2 diabetes
- Self-referral to hospital with sore skin
- Leakage
- Large parastomal hernia
- Difficulty placing pouch – having to lie down
- Creases in wafer due to shape of hernia

TREATMENT

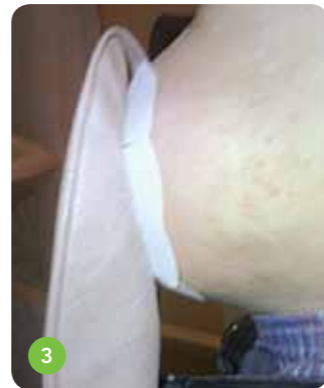- Hospital Stoma Nurse observed pouch changing technique
- Changed pouch to Confidence® Natural because of its Aloe Vera content and Salts British Skin Foundation accreditation
- Advised to use a barrier cream for 2 weeks
- Referral to Community Stoma Care Nurse

RESULTS USING CONFIDENCE® NATURAL

- Reviewed after 2 weeks (Ref 1)
- Skin had healed
- Barrier cream only used for 3 pouch changes, as patient was unable to apply
- Skin looked and felt well moisturised
- Little residue on skin
- No leakage (Ref 2)
- Patient found pouches easy to remove
- Comfortable to wear
- No “sharp edges”
- Able to place the pouch while standing (Ref 3)



- Five-sided Flexifit® wafer moulded around his stoma
- No creases on the wafer
- Patient is very happy with the pouch (Ref 4)
- He will continue to use
- His confidence is growing and he has now started going out again



Easy to use and comfortable to wear

Gave patient confidence to start going out again

Skin condition improved quickly

CONCLUSION

- Confidence® Natural was easy for this patient to use and comfortable for him to wear
- Skin condition improved quickly
- The Flexifit® wafer provided an excellent fit, giving this patient the confidence to start going out again

PATIENT CASE STUDY No.5 (UK) Confidence® Natural Urostomy


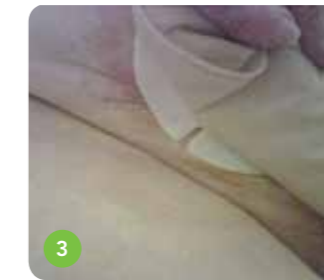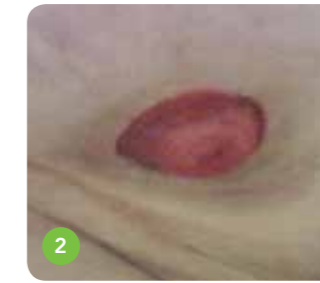
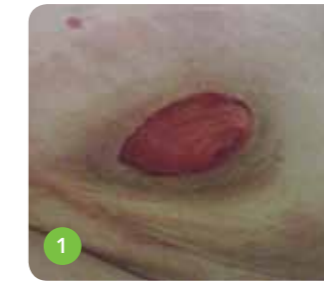SKIN

PATIENT HISTORY

- 80 year old female
- Bladder cancer 13 years ago. She underwent a radical cystectomy, with formation of a urostomy
- For many years, the patient used a 2-piece urostomy product and had no problems with management
- However, over the last 3 – 4 years, she developed problems with leakages but continued the same stoma care regime
- Until last year, she was leaking daily, day and night
- The patient lost her confidence to go out and started to become depressed
- At this point, she was referred to the Community Stoma Care Nurse

OBSERVATION ON FIRST HOME VISIT

- It was noted that the patient had become very concerned regarding the problems with her urostomy, feeling that she was becoming housebound due to the leakages
- She was also very emotional because of the situation, becoming tearful at times
- After a medical history was recorded, we discussed the stoma problems: the patient had used the same 2-piece pouch for the last 13 years and had only recently started to use seals and wafer extenders to solve the problems, but with no success
- She reported a change in shape to her abdomen, of which she had become self-conscious, and that the peristomal skin felt sore and itchy most of the time
- On examining this patient, it was noted that she had a parastomal hernia. This bulge had changed the position of stoma, creating an uneven surface and skin creases on the peristomal area (Ref 1 & 2)



TREATMENT

- The patient was very reluctant to try a different pouch but we both felt that other accessories might not be the solution
- Our aim was to improve pouch adhesion and stop the leakages
- I recommended the new Confidence® Natural 1-piece pouch, as it is designed to mould around contours of the body and has a stronger adhesive, to prevent breakdown from the urine

RESULT

- The pouch stayed intact for 2 days and, for a further 2 weeks, had the same wear time
- Patient was reluctant to use a different pouch but found the Confidence® Natural pouch easy to apply, fitting her body shape and adhering well to the skin (Ref 3 & 4)

OUTCOME

- Patient no longer has any daytime or night time leakages, feels more secure with the Confidence® Natural pouch and it fits around her parastomal hernia shape
- The hydrocolloid wafer infused with Aloe Vera improved the problem of her feeling sore on the peristomal skin and stopped the itchy skin, which was an added result that we were not expecting
- But, most importantly, the Confidence® Natural urostomy pouch gave this patient the confidence to start going out again and enjoying her life without the fear of leakages

No more leaks or itchy skin

Regained confidence to enjoy her life again

CONCLUSION

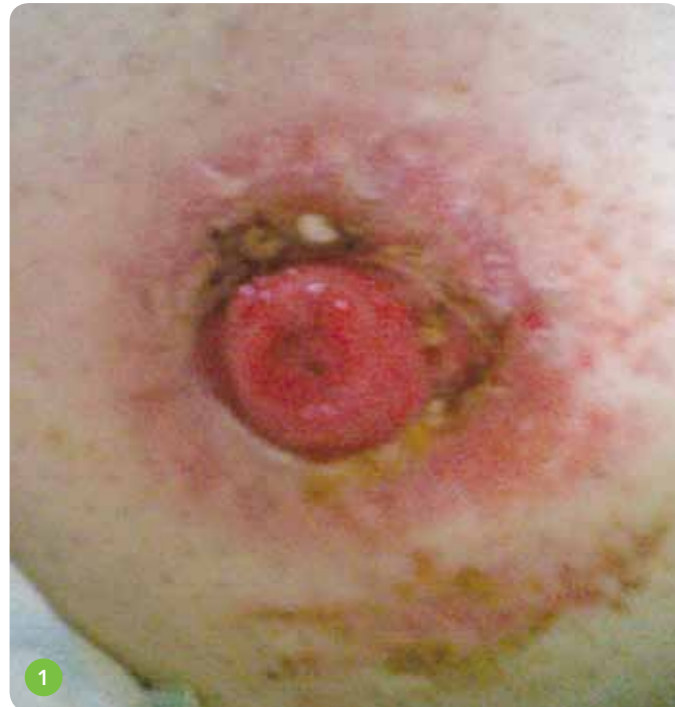- Confidence® Natural prevented leakage for this patient
- The pouch provided a longer wear time, thus assisting the peristomal skin healing process
- The Aloe Vera helped soothe the skin and stopped the itchiness previously experienced
- This patient regained confidence to enjoy her life again

PATIENT HISTORY

- 60 year old male
- Stoma formed in 1988 following injuries incurred while working in bomb disposal
- 22 trouble-free years followed
- Readmitted, haemorrhaging from stoma in Oct 2010
- Further admissions, with suturing and refashioning
- Finally discharged in June 2011
- Referral received from hospital Stoma Nurse

INITIAL OBSERVATION

- Excoriated peristomal skin (Ref 1)
- Cavity from 10 – 4 o'clock
- Fistula around the 3 o'clock region



PRODUCTS BEING USED AT TIME OF VISIT

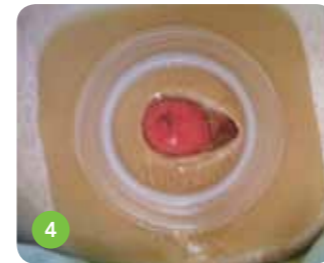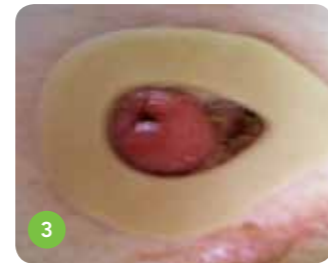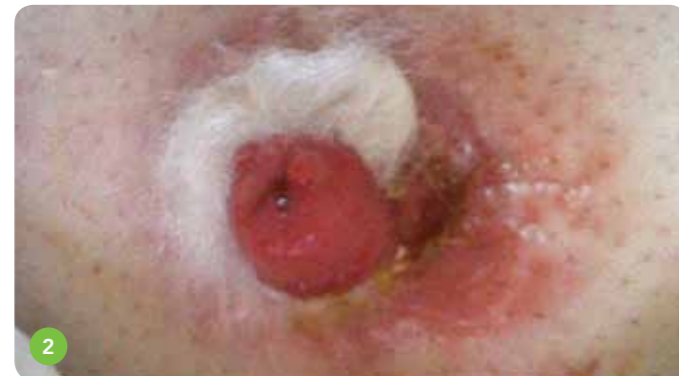- Sorbsan packing
- Hydrocolloid paste
- Duoderm hydrocolloid square
- 2-piece system
- Micropore tape

PROBLEMS BEING EXPERIENCED

- Leakage from fistula seeping under Duoderm
- Sorbsan soaking up faecal fluid, preventing healing of the cavity
- Base plate lifting off
- Resultant sore skin
- Pouch lasting less than 24 hours
- Restriction to social activities, and lack of confidence

INITIAL TREATMENT

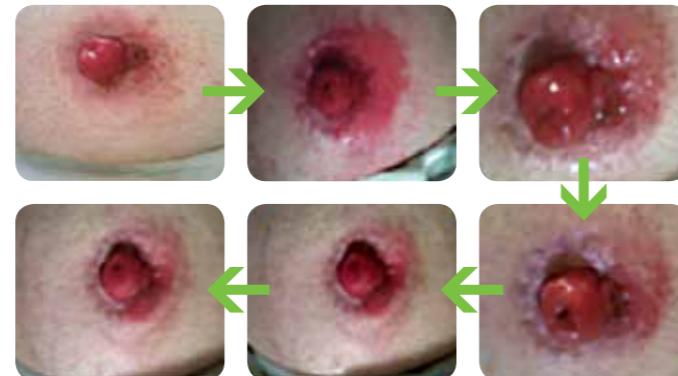- Cavity packed with Sorbsan. Protective paste around fistula skin edge (Ref 2)
- SecuPlast® Mouldable Seal. Hydrocolloid paste (Ref 3)
- Convex ring to give base plate convexity as patient reluctant to try different product. Frequency of visits: 3 times a week plus emergency calls (Ref 4)



FOLLOW-UP TREATMENT

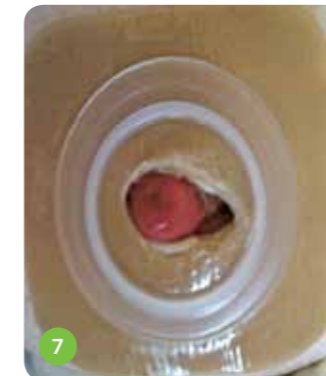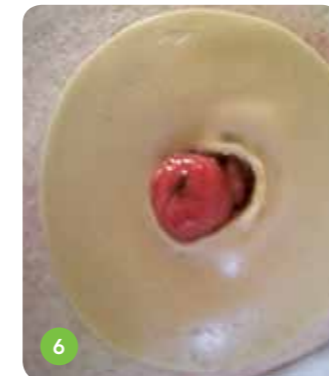
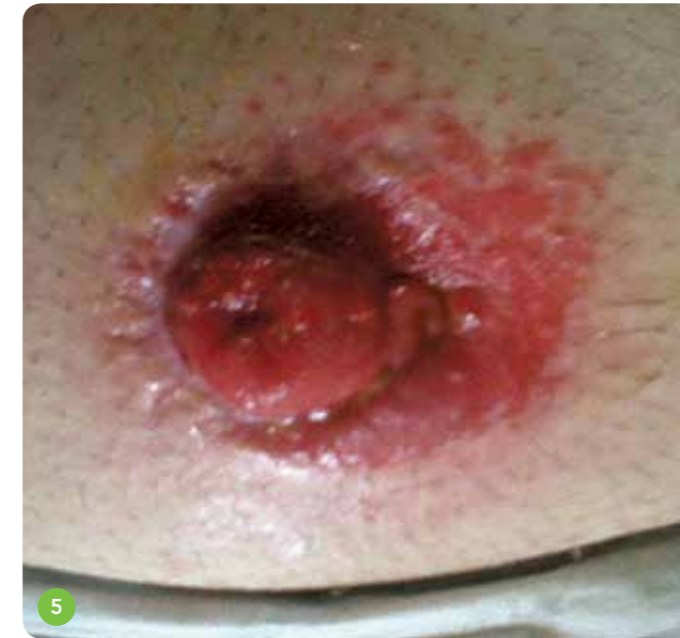- Treatment continued over 2 weeks, with minimal improvement
- District nurse now supporting: 1 visit per week
- Leakage into Sorbsan reduced
- Skin around fistula deteriorated
- Suggested patient use Harmony® Duo 2-piece system with Flexifit® flange
- Patient had allergic reaction to the hydrocolloid surround and reported faecal fluid seeping through the tape surround
- Loss of confidence, changed back to original products at patients request

PROGRESS THROUGH INITIAL TREATMENT



CHANGE OF TREATMENT

- Excoriated peristomal skin, causing pain and discomfort (Ref 5)
- SecuPlast® Mouldable Seal changed to large size (Ref 6)
- Flange made convex with a convex ring (Ref 7)

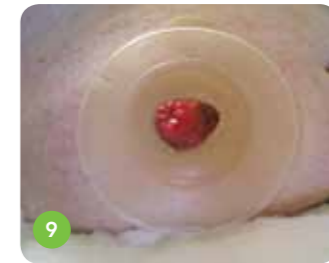
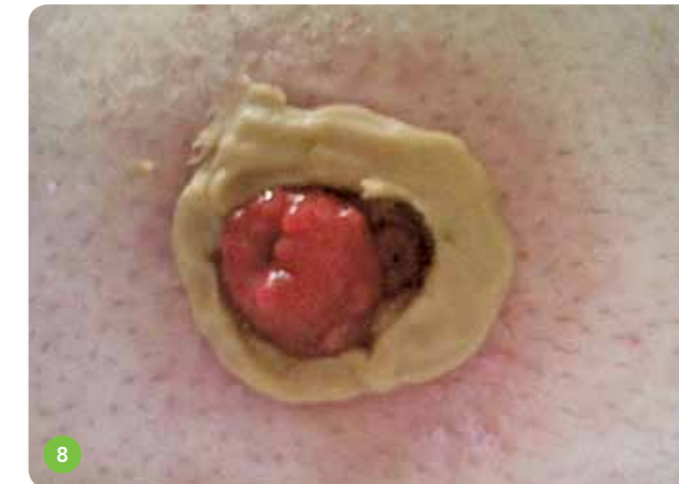

PHYSICAL AND PSYCHOLOGICAL EFFECTS

- 1 week on: cavity healing well, Sorbsan discontinued, leakage from fistula still causing problems to skin
- Flanges not lasting more than 24 – 36 hours, patient repairing leakage point as unable to change himself
- Emotionally distressed due to frequent episodes of leakage in bed and on the carpets
- Unable to go out of the house as unaware if leakage will occur, feeling very trapped and unable to cope
- Letter plus photographs were sent to consultant for possible re-fashioning
- Patient asked to try Harmony® Duo again

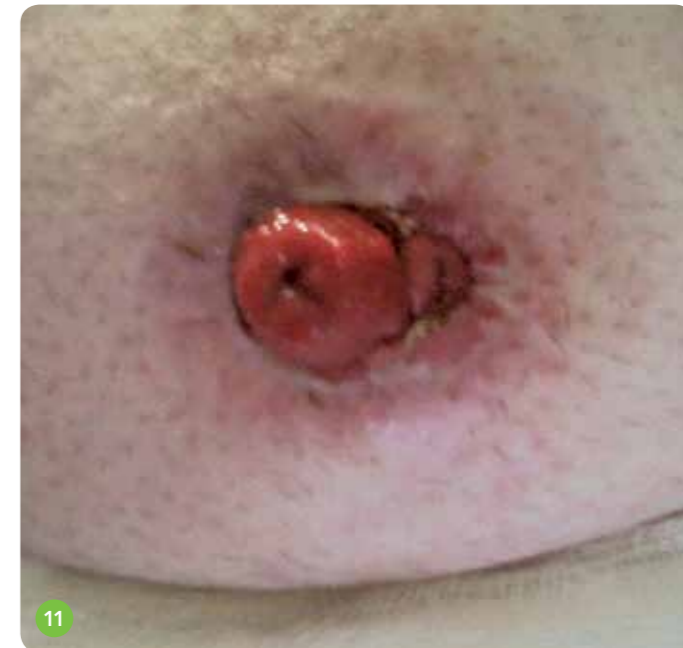HARMONY® DUO WITH FLEXIFIT® FLANGE

- Protective paste to point of fistula. Ring of hydrocolloid paste (Ref 8)
- Flange applied. Excess paste removed with probe. Inner edges sealed (Ref 9)
- Pouch secured. SecuPlast® Hydro Aloe strips applied over flange. Micropore at patient's request (Ref 10)

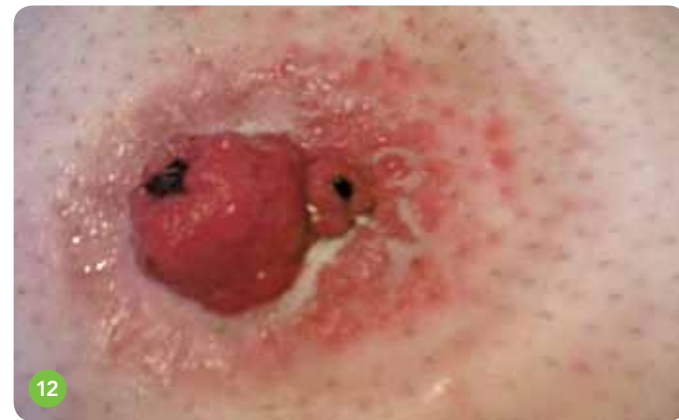

IMPROVEMENTS

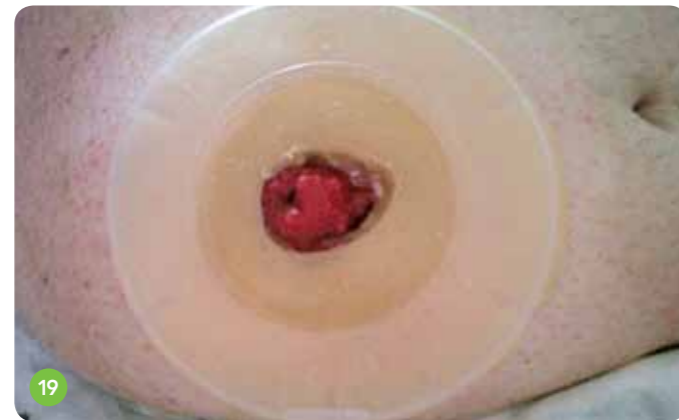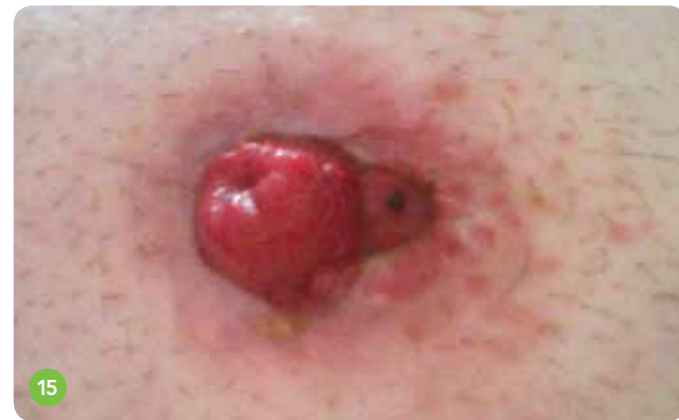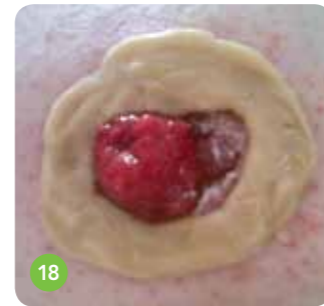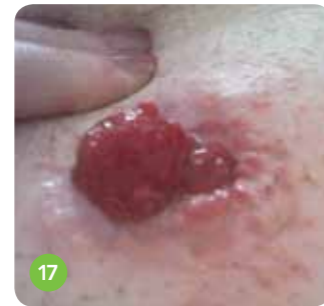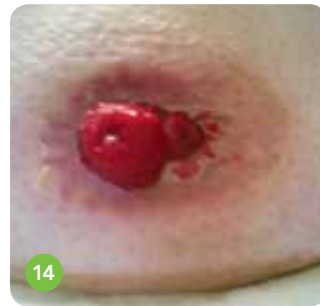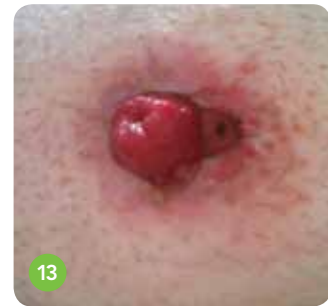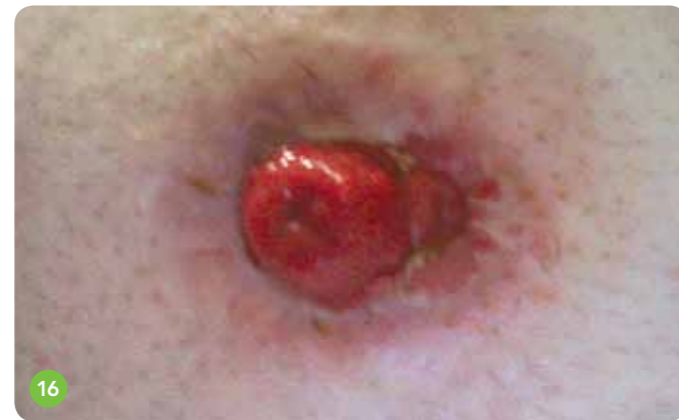- Flange lasting longer
- Leakage not penetrating through hydrocolloid paste
- Peristomal skin improving (Ref 11)
- Confidence building up, and patient starting to go out for walks
- Appointment received for consultant
- Mood lifting



RESULTS



ASSESSMENT 1 WEEK LATER



- Flange *in situ* for over 36 hours
- Protective paste discontinued
- Leakage contained with hydrocolloid paste
- Further improvements visible (Ref 16–19)
- Patient happy to continue with Harmony® Duo with Flexifit® flange
- Appointment received to see Consultant

Improved physical and emotional well-being

Allowed patient freedom to leave the house

Gained patient trust in the products used

CONCLUSION

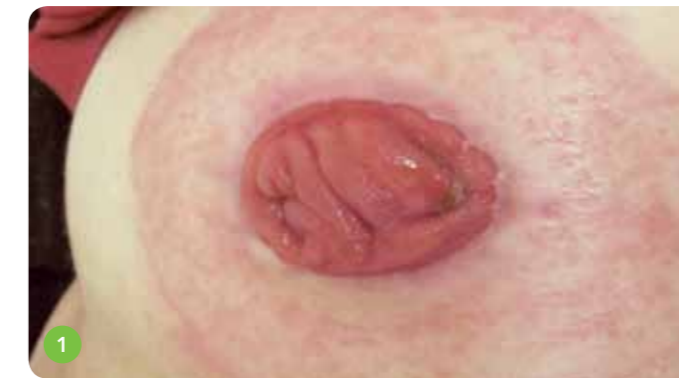- The Harmony® Duo Flexifit® flange has provided benefits to the patient, both in terms of improved physical and emotional wellbeing
- Provided an alternative to convexity
- Decreased the frequency of flange changes
- Allowed patient freedom to leave the house
- Gained patient trust in the products used

PATIENT HISTORY

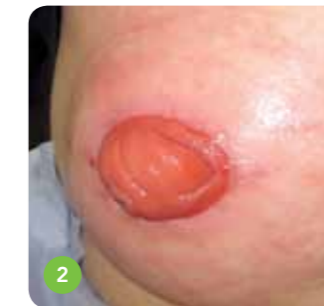- 61 year old female
- History of abdominal pain, bloating, vomiting and change of bowel habit
- Colonoscopy revealed an annular stricture in distal sigmoid colon 15cm, impassable, biopsies taken
- Histology result came back as Moderately Differentiated Adenocarcinoma
- Symptoms of obstruction: being sick and loss of appetite
- December 2010: Laparoscopic assisted loop transverse defunctioning colostomy
- The patient was using a drainable pouch as her output was very erratic
- Discharged home after a couple of weeks, managing the stoma well
- I tried contacting the patient after 1 week of discharge to arrange a home visit – left messages on the phone but there was no response
- I received a call from the patient saying that her skin was so red, sore and very itchy – she offered to come to the clinic for review

TREATMENT

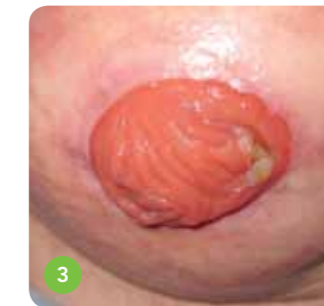- On examination, the colostomy was healthy but surrounding skin was very red and excoriated
- She had suffered an allergic reaction to the appliance she was using (Ref 1)
- Advised her to clean surrounding skin with water, dry, and then use a new appliance
- The new appliance recommended was Confidence® Natural Standard drainable pouch (ND13)
- Immediately after the pouch was put on, the patient said "It has a soothing, different feeling."



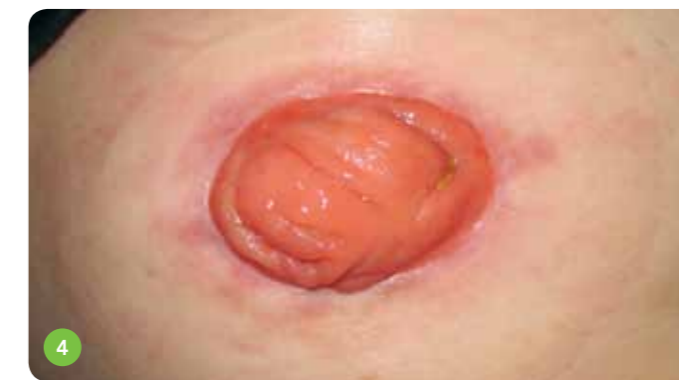Ref 1: Transverse loop colostomy with redness around stoma, same shape as the wafer.



Ref 2: Redness was still present.



Ref 3: Redness had nearly gone.



Ref 4: Skin was perfect.

I loved it – it's made a big difference in my life

- After a week, I asked the patient to come to clinic for review (Ref 2) – redness still present
- Patient expressed that the pouch made a difference
- Very comfortable and no itchiness at all
- Redness was still noted but fading away
- Patient started her first cycle of chemo and was admitted to the hospital. She was very sick and unwell
- Only 4 days after I last saw her, I visited the patient in the ward to check (Ref 3) – the redness had nearly gone
- Patient came to clinic for review
- She said her skin was perfect – she didn't feel that she had a pouch on – very comfortable (Ref 4)
- "I loved it, you might think I'm mad. It's true: since you changed the pouch to this one, it's made a big difference to my life."

CONCLUSION

- From my experience, when a patient complains of itchiness under their pouch and redness on their skin, immediately, and without a second thought, I will put them on Confidence® Natural
- Confidence® Natural is brilliant; I highly recommend it to patients who suffer a skin reaction to other pouches

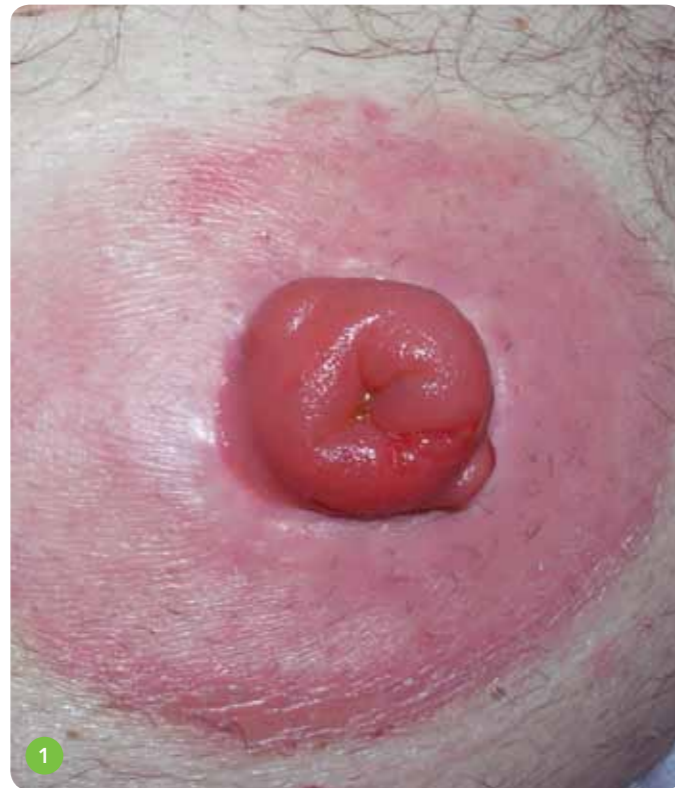PATIENT HISTORY

- 67 year old male
- Married and working as a taxi driver, running his own company
- Rectal cancer at 5cm level, surgery after short radiotherapy
- Rectal excision with permanent colostomy in May 2008
- Radical surgery

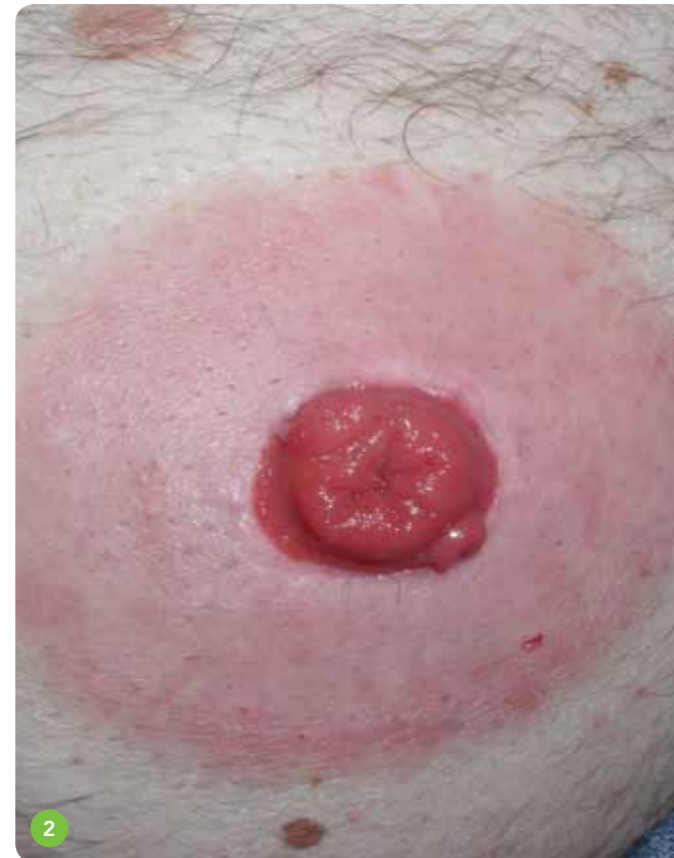OBSERVATION ON REFERRAL

- At the first post-surgery visit to the stoma clinic, the patient receives information about one-piece pouches and tests all the pouches available on the market
- He decides on two different pouches and is pleased with them
- Tries irrigation after about 6 months and starts to irrigate every other day
- The area around the stoma begins to bulge more and more, and at the one-year check-up, a peristomal hernia is found
- Skin around the stoma also shows redness in patches
- The patient is recommended to use Pevisone® (topical steroid cream) for two weeks and pays a visit after four weeks. He is then much bothered by his hernia, now CT verified, and is scheduled for surgery
- The peristomal skin is still not healed, and there is still redness with folliculitis
- Instructed on shaving the peristomal skin, to be careful when changing pouches and to use the remover pad to reduce the risk of stripping damage
- Starts a short treatment with Kenakombin® (corticosteroid) that the patient has used previously, prescribed by a dermatologist
- The patient does not return to the out-patient clinic for about 5 months. The patient requires treatment of his

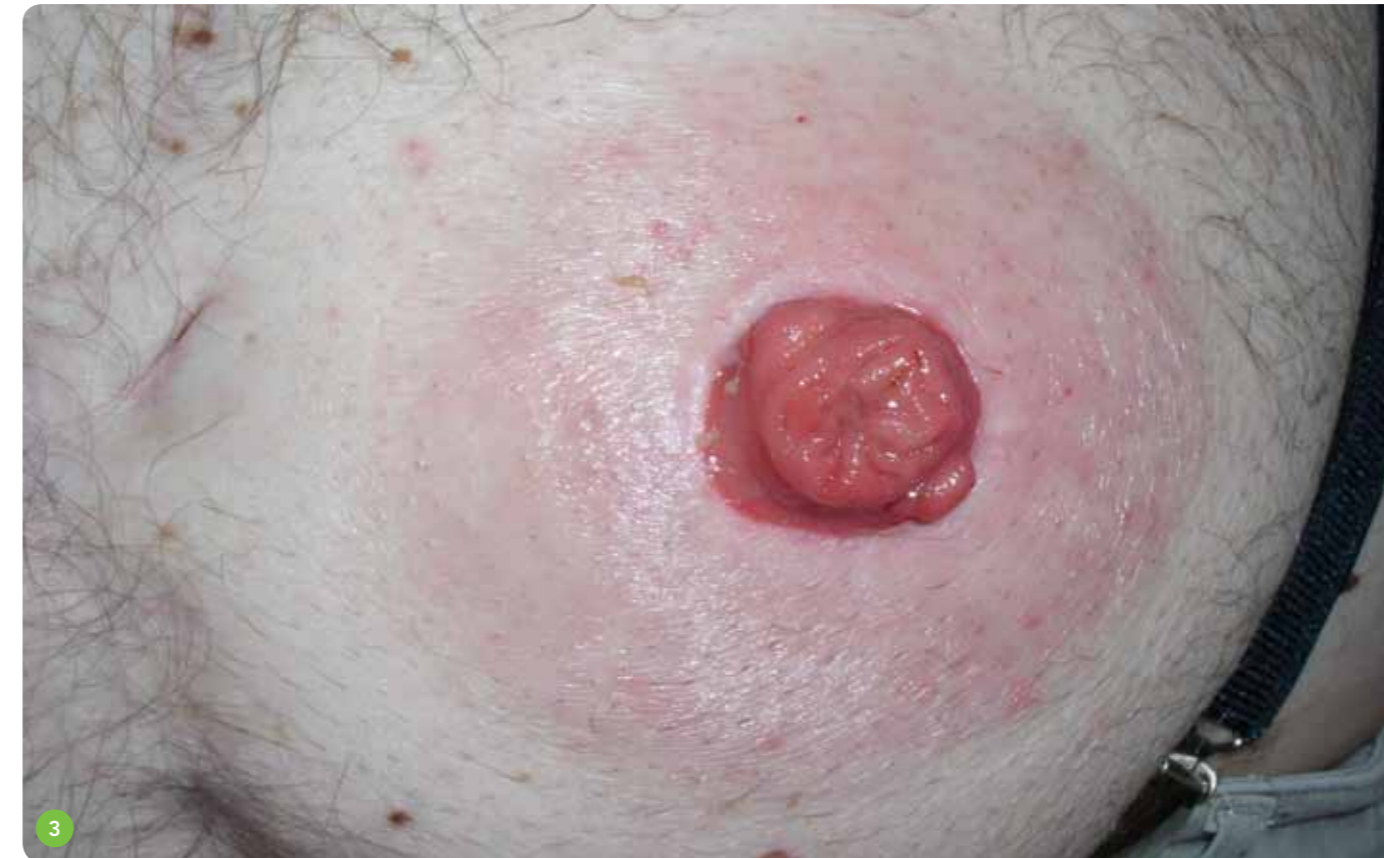- irritated skin and expresses that the bag often lifts from the skin and that it has to be changed many times a day
- The skin is now very red under the entire wafer: dry, flaky skin on the edges, and it also bleeds in some places
- The patient does not want to change to another pouch from another company and is happy with the one he has, but is recommended a treatment with Betnovat with Chinoform® every other day for two weeks, and to be very careful during bag changes
- The patient cancels the follow-up appointment as he feels the skin now looks better



Ref 1: The skin prior to using Confidence® Natural



- The patient is operated on in 2010 for his hernia. During this time, the patient only has telephone contact with the stoma clinic for stoma care prescription
- April 2011 – the patient is hospitalised on the ward because of constipation. When looked at, the skin is substantially red throughout the whole peristomal area
- The patient states that it always looks like that. He usually needs to change his bag four times a day and always feel insecure about using it



TREATMENT

- The patient is now recommended to switch to Confidence® Natural and not to use any other treatment as there have been no previous signs of improvement
- On a follow-up visit at the stoma outpatient clinic 2 weeks later, the patient is very satisfied with the new pouch. Skin irritation has begun to fade away after a few days usage and is now much better (Ref 2)
- The patient feels that the bag has a good fit, with no leakage or pancaking problems that he was troubled by in the past. He expressed that he'd like to continue with this pouch
- At the additional follow-up after 5 weeks, (7 weeks after switching to a new bag), the patient is still very happy, with the peristomal skin now almost normal looking (Ref 3)

Fits much better and does not lift off

Feels completely safe, confident and happy

Less frequent changes and no need for accessories

CONCLUSION

- The patient feels confident with his new bag; does not need any accessories that he previously used, such as remover spray; and changes the bag less often, as the new bag fits much better and does not lift off
- Changes are now limited to 1–2 times a day and then only due to the amount of faeces in the bag
- The patient now feels completely safe and happy with his new bag

PATIENT HISTORY

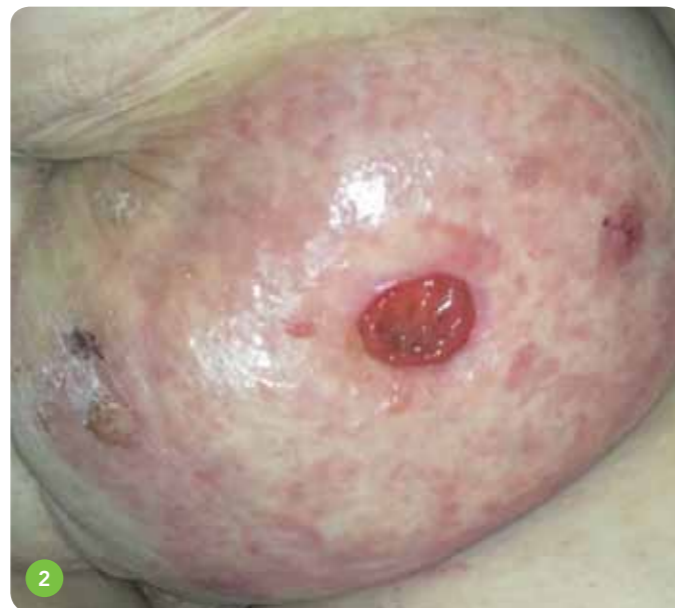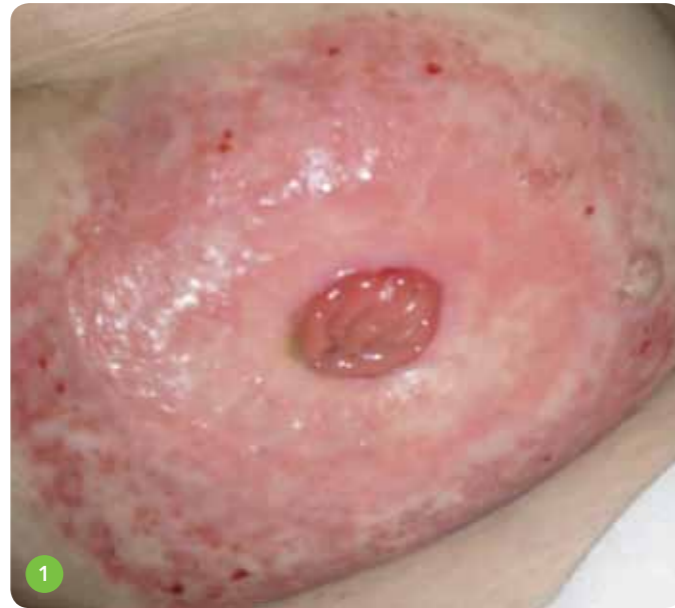- 82 year old female
- APER and end colostomy formed in 2009 for Dukes B carcinoma of rectum
- Very active, well educated, keen gardener, generally fit
- Had lost contact with NHS Stoma Care Team
- Self-referral, with a bulging abdomen and extremely sore excoriated skin which had failed to heal
- Very low mood

OBSERVATION ON REFERRAL

- Severe erythematous peristomal skin
- Bulging abdomen with uneven contours and small parastomal hernia
- Experiencing pancaking and leaks
- Pouches would not stick to weeping skin, frequent changes exacerbating the problem
- Severely lacking confidence, with potential to socially isolate herself
- Using a combination of two different pouches with skin protective film wipes and medical adhesive remover wipes
- Red, angry and weeping skin with a wart at the left outer edge
- Severe itching and discomfort
- Using skin protective film at this point
- Skin trauma visible due to frequent pouch changes and removal technique (Ref 1)

PRESCRIBED TREATMENT

- To stop using medical adhesive remover and skin protective film wipe in order to assess whether or not the wipes were causing a contact dermatitis. Shown how to remove pouch effectively without chemicals



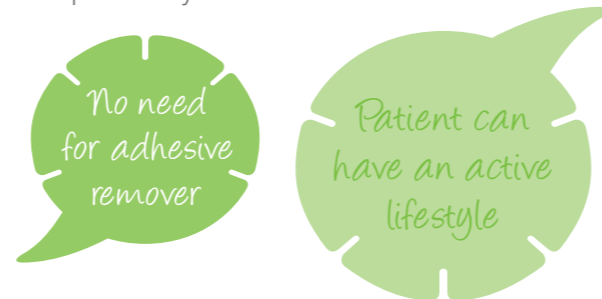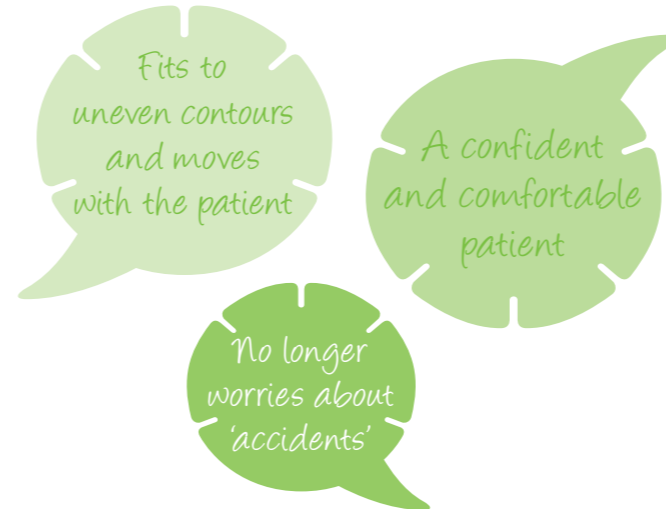
- Advised to use water to wash; and pat dry with soft dry wipe, avoiding rubbing to prevent further skin trauma. Apply Confidence® Natural Closed, trying to limit to twice daily changes

RESULTS

- One week later, the skin was much improved. Still red and raised areas, but not weeping and the patient was feeling more positive. There was visibly less skin trauma due to improved pouch removal technique (Ref 2)
- A further 8 weeks later, healthy, intact peristomal skin with continued use of Confidence® Natural (Ref 3)
- The pouches are easily removed without adhesive remover. As a result, there is no chemical irritation or skin trauma
- The warts have also healed

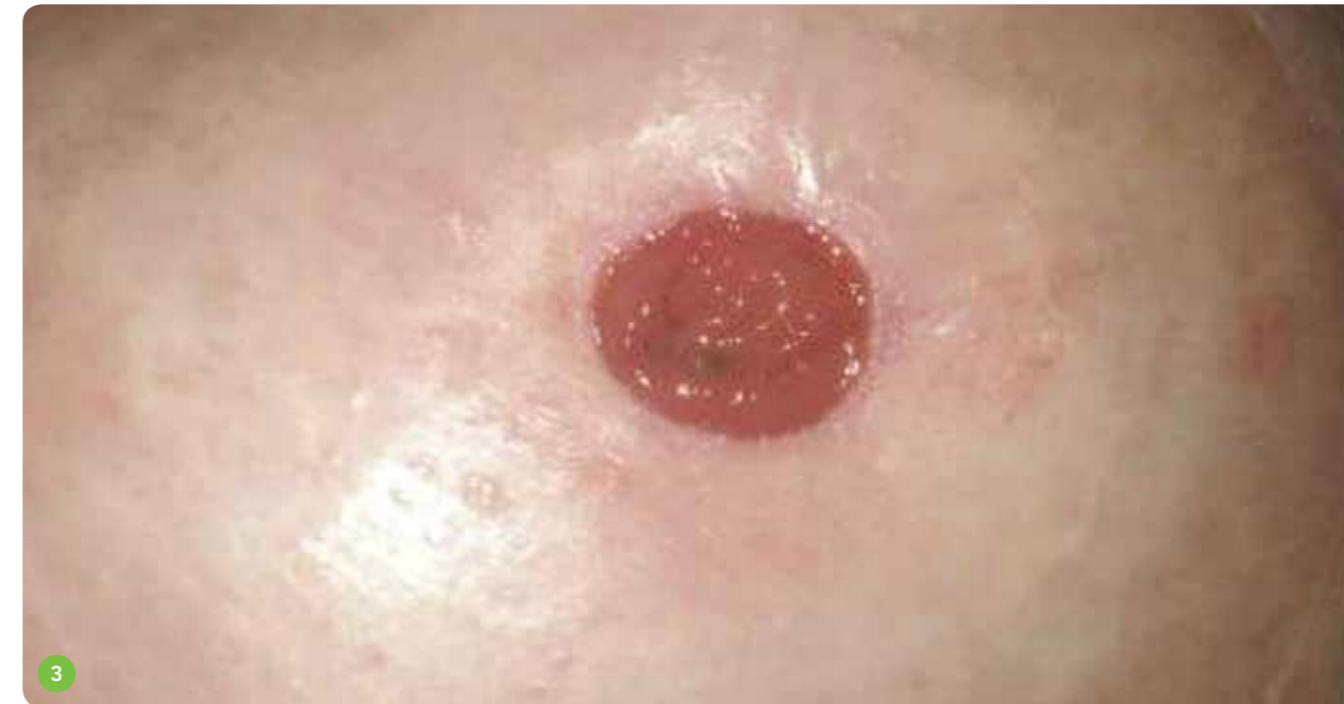OUTCOME

- Healthy, intact peristomal skin. Confidence® Natural fits to uneven contours and moves with the patient, allowing her to have an active lifestyle
- A confident patient, who is comfortable and no longer worries about 'accidents'
- Still experiences some pancaking but attributes this to diet and fluid intake, and is happy to manage this independently



CONCLUSION

- Confidence® Natural is flexible and fits uneven contours
- Confidence® Natural moves with the patient and will remain intact even when bending, stretching and with increased activity
- Confidence® Natural is easily removed without the need for adhesive removers
- With the combination of discontinuing the skin protective film wipe and adhesive remover; and using the flexible, skin-friendly Flexifit® wafer, the outcome was very satisfactory



Salts Healthcare wishes to thank the Stoma Care Nurses who contributed case studies, and the following hospitals:

- Stoma Care Department, Imperial College Healthcare NHS Trust
- Stoma Care Department, Southampton University Hospitals NHS Trust
- Helsingborgs Lasarett, Sweden